

An Observational Study on Evaluation of IOTA Ultrasound Simple Rules to Distinguish Benign and Malignant Ovarian Masses and Histopathological Correlation in a Tertiary Care Hospital

Amatul Kareem Sumaya¹, Banavath Swetha^{1*}, Aithagani Ramachandraiah², Nadeem Ahmed¹, Sunitha Bajaj¹

¹Department of Radio-diagnosis from Osmania Medical College, Hyderabad, India

²Department of Radio-diagnosis from Osmania Medical College, MNJ Institute of Regional Cancer Center, Hyderabad, India

*Corresponding author: Department of Radio-diagnosis from Osmania Medical College, Hyderabad, India. Email: drbanavaths@gmail.com

Received 2023 April 30; Accepted 2023 May 29.

Abstract

Background: The international ovarian tumor analysis (IOTA) study technique is a specialized method for classifying and identifying adnexal growths. It employs 10 simple ultrasound directions to characterize masses as benign or malignant.

Objectives: This study aims to provide pre-operative information to help gynecologists manage ovarian masses, avoiding delays in malignancy treatment and unnecessary surgery for benign lesions.

Methods: This was a hospital-based observational study conducted in the radiology department on patients with clinical diagnoses of ovarian masses from August 2020 to March 2022 by prospective randomized sampling method. Patients with suspected ovarian pathology were evaluated using IOTA ultrasound rules and designated benign or malignant. The patients underwent a thorough history and clinical examination. Ultrasound was used to confirm the ovarian origin of the mass and differentiate it as benign or malignant. A transvaginal ultrasound was performed where necessary. Histopathological examination was the gold standard to confirm ultrasound and Doppler findings. Descriptive stats: Frequencies/percentages for categorical data, mean \pm SD for normal, median with IQR for non-normal. Uncertainty measured by 95% CI.

Results: During the study, 50 women were eligible for the study, and the mean age of the participants was 45.3 years. Of 50 patients who underwent surgery, 38 cases were considered benign based on IOTA USG rules, of which 35 were benign and 3 were malignant histologically. Eight cases were considered malignant based on IOTA USG rules, of which 6 were malignant and 2 were benign. Four cases were considered indeterminate, with two being benign and two being malignant histologically. If inconclusive cases are classified as malignant, the sensitivity and specificity are 75% and 88%, respectively.

Conclusions: USG is an easily available imaging tool that can be used as an initial modality in evaluating ovarian masses. IOTA simple ultrasound rules have diagnostic accuracy in distinguishing benign and malignant ovarian masses and help in management.

Keywords: IOTA, USG rules, International Ovarian Tumour Analysis, Ovarian Cancer.

1. Background

In the present era, when medical science is booming with all the technological advances, Ovarian carcinoma is still a global problem affecting millions of women and their families.

The frequency of ovarian cancer has grown in recent years. Ovarian cancer accounts for 3.6% of all cancer cases, with a 4.3% death rate. According to the American Cancer Society and "The National Cancer Institute," 14,270 women will die from ovarian cancer-related complications yearly, with an estimated 21,980 new cases of the disease being discovered yearly (1).

Ultrasonograms are the first imaging modality for adnexal mass lesions. The largest study on ultrasonography diagnosis of ovarian pathology is the international ovarian tumor analysis IOTA trial. The IOTA acronym refers to the International Ovarian Tumor Analysis Group. The IOTA models significantly outperform subjective assessments regarding impartiality, simplicity, and application (2). They offer clear guidance for achieving a precise pre-surgical diagnosis. Numerous international and external validation investigations have supported the reliability and correctness of the IOTA Simple Rules and the IOTA



logistic regression models (3).

The IOTA group established a systematic method for categorizing adnexal masses before surgery. The study's 10 basic ultrasonography principles, which showed excellent sensitivity and specificity and were applied to a wide range of malignancies, were a notable strength (4). The mass is categorized as malignant or benign depending on whether one or more M-rules are used in the absence of a B-rule or one or more B-rules in the absence of an M-rule. The mass was classified as inconclusive if both M-rules and B-rules apply or if neither rule applies (5-14).

The tumors on the ovaries might be benign or malignant. Simple, functional cysts, serous cystadenomas, mucinous cystadenomas, endometriotic cysts, fibromas, thecomas, and Brenner tumors are all benign lesions. Serous cystadenocarcinoma, mucinous cystadenocarcinoma, endometriotic carcinoma, immature teratoma, dysgerminoma, and Krukenberg's tumor are malignant lesions. Diverse age groups have different causes of adnexal mass lesions (15).

Ultrasound has the advantage of portability, uses non-ionizing radiation, and is easily available. With the advantages of ultrasound and IOTA study, it is to characterize ovarian masses into benign and malignant. Characterizing the lesion, whether benign or malignant, is crucial in early management and prevents delay in treatment.

2. Objectives

This study aims to provide a pre-operative evaluation of ovarian tumors and to distinguish them into benign and malignant tumors based on simple ultrasound rules and correlate with HPE and help the gynecologist in planning the management of ovarian masses (16). It helps to avoid unnecessary biopsies and surgeries in benign lesions and to optimize surgical outcomes in malignant lesions. IOTA rules are used preoperatively to decrease ambiguity, increase correct diagnosis, and optimize patient management (17-20).

3. Methods

This study was conducted in the Department of Radio Diagnosis over 18 months (AUGUST 2020 to MARCH 2022).

Informed written consent of participating individuals will be taken. All the information is collected prospectively, including demographic characteristics and time of onset of symptoms. The patients are clinically evaluated initially by a gynecologist. Data will be collected from at least 50 cases of suspected or accidentally detected ovarian lesions referred for USG. Data will be collected using SAMSUNG RS80A ULTRASOUND MACHINE. After informed consent, the patient is examined supine with a full bladder with a transabdominal ultrasound probe. A transvaginal probe is used wherever necessary. Data will also be collected. The lesion will be characterized based on size, shape, echotexture, septations, papillary projections, solid components, margins, and color Doppler findings. IOTA simple rules are applied to characterize the lesion into benign and malignant. Descriptive statistics were calculated for each variable, using frequencies and percentages for categorical variables, mean \pm standard deviation (SD) for normally distributed data, or median and interquartile range (IQR) for non-normally distributed data. The 95% confidence interval (95% CI) was adopted as a measure of uncertainty around an estimate.

The statistical program BM SPSS Statistics for Windows, version 22.0 (IBM Corp., Armonk, NY, USA) was used. Descriptive statistics on frequencies and percentages (%) for qualitative variables. Categorical variables are expressed as Number of patients and percentage of patients. The chi-square test was used to test the significance of categorical variables, and $P < 0.05$ is considered the significance level.

4. Results

In the present study, a total of 50 subjects were included in the study. Ovarian lesions were common between the age group 26 - 40 years ($n = 22$, 44%), as shown in Table 1. A total of 36 cases are verified histologically. Twenty-six cases were considered benign based on IOTA USG rules, of which 23 turned out benign, and 3 became malignant histologically. Eight cases were considered malignant based on IOTA USG rules, out of which 6 turned out to be malignant, and 2 turned out to be benign. Four cases were considered indeterminate, of which 2 were benign and 2 were malignant histologically.

Table 1. Age Distribution of Ovarian Masses

Age, y	Cases, No. (%)
15 - 25	7 (14)
26 - 40	22 (44)
41 - 55	12 (24)
56 - 70	9 (18)
Total	50 (100)

Table 2 showed that the unilateral lesions ($n = 43$, 86%)

were the most common than the Bilateral lesion in the

current investigation.

Table 2. Laterality of Ovarian Masses

Laterality	Cases, No. (%)
Unilateral	43 (86)
Bilateral	7 (14)
Total	50 (100)

In the present study, Table 3 showed the most common benign lesions, accounting for 76% (n = 38) (Table 3).

Table 3. Type of Pathology of Ovarian Masses Based on IOTA Rule

Type of Pathology	Cases, No. (%)
Benign	38 (76)
Malignant	8 (16)
Indeterminate	4 (8)
Total	50 (100)

In the present study, serous cystadenomas are the most common benign lesions (n = 16, 32%), followed by Simple ovarian cysts (n = 16, 32%) and Hemorrhagic cysts (n = 12, 24%) (Table 4).

Table 4. Distribution of Benign Ovarian Pathologies

Pathology	Cases, No. (%)
Simple ovarian cyst	16 (32)
Hemorrhagic cyst	12 (24)
Endometriotic cyst	8 (16)
Serous cystadenoma	32 (64)
Mucinous cystadenoma	8 (16)
Dermoid	4 (8)

Serous Cystadenocarcinoma is the most common malignant ovarian pathology at 100% (n = 8), followed by Mucinous cystadenocarcinoma and metastasis, i.e. 50% (n = 4). However, Germ cell tumors and Dysgerminoma were observed to be the least, i.e., 25% (n = 2) (Table 5).

Table 5. Distribution of Malignant Ovarian Pathologies

Pathology	Cases, No. (%)
Serous cystadenocarcinoma	8 (100)
Mucinous cystadenocarcinoma	4 (50)
Metastasis	4 (50)
Germ cell tumor	2 (25)
Dysgerminoma	2 (25)

Figure 1 shows that the unilocular ovarian masses are the most common ovarian pathology, i.e., 66% (n = 33).

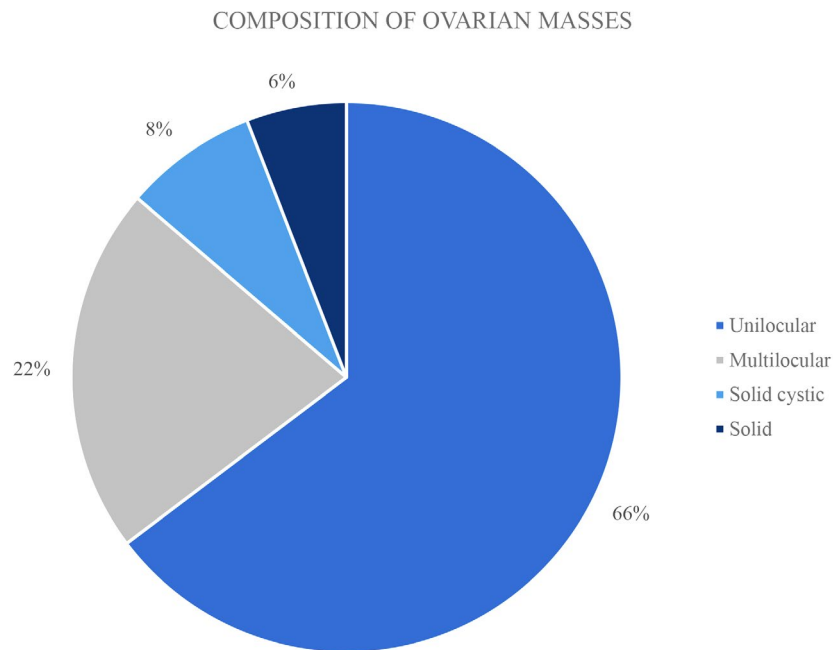


Figure 1. Composition of ovarian masses

Septations were seen in 11 cases, 22%. Solid components were seen in 5 cases, 10%. Among the B features, the B5 feature is the most common (n = 32, 64%), i.e., color score 0 (no blood flow), followed by the B1 feature (n = 30, 60%), i.e., Unilocular cyst < 10 cm (Table 6).

Table 6. Presence of Septations and Solid in Ovarian Masses

Variables	Cases, No. (%)
Septations	
Present	11 (22)
Absent	39 (78)
Solid Component	
Present	5 (10)
Absent	45 (90)

According to Table 7, among the M features, the M4 feature is the most common (n = 5, 10%), i.e., irregular mul-

tilocular solid ovarian lesions, followed by the M1 feature (n = 4, 8%), i.e., irregular solid tumor.

Table 7. B and M Features in Ovarian Masses

B Features	No. (%)	M Features	No. (%)
B1	30 (60)	M1	4 (8)
B2	1 (2)	M2	2 (4)
B3	1 (2)	M3	2 (4)
B4	6 (12)	M4	5 (10)
B5	32 (64)	M5	0 (0)

The result also showed necrosis, solid components, and calcification on USG to be featured, suggesting malignant lesions (Table 8).

Table 8. Additional Features in Ovarian Masses

Additional Findings	No. (%)
Calcification	1 (2)
Fat fluid level	1 (2)
Ascites	5 (10)

In the present study, Figure 2 presented the B5 feature as the most common (n = 32, 64%), i.e., color score 0 (no blood flow), followed by the B1 feature (n = 30, 60%), i.e., Unilocular cyst <10 cm.

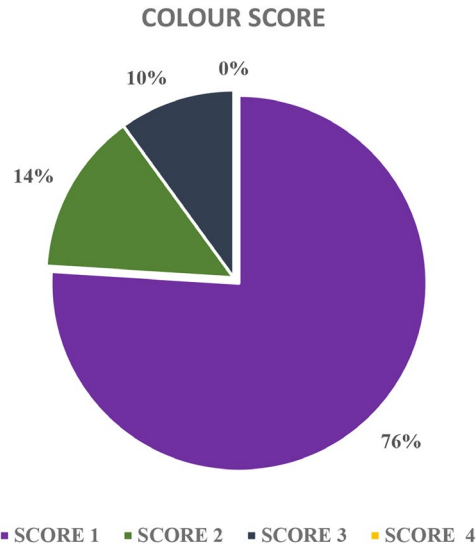


Figure 2. Colour score of ovarian masses on Doppler

When compared with a histopathological diagnosis, there were 3 discordant cases in the Study. Two mucinous cystadenocarcinomas were diagnosed as benign masses

(Mucinous cystadenoma) using IOTA USG simple rules as stated in Table 9.

Table 9. Comparison of IOTA Simple Rules with HPE Diagnosis

Nature of Mass as APER IOTA Rules	No. of Cases	HPE-Benign	HPE-Malignant
Benign	38	35	3
Malignant	8	2	6
Indeterminate	4	2	2
Total	50	39	11

In the present investigation, using USG, the benign ovarian masses were compared with malignant ovarian masses. Benign ovarian masses showed higher predomi-

nance towards sensitivity and positive prediction values, i.e., 92.10% and 89.70%, as shown in Table 10.

Table 10. The Sensitivity/Specificity Statistical Results of Benign and Malignant Ovarian Masses

Statistics	USG in Benign Ovarian Masses, %	USG in Malignant Ovarian Masses, %
Sensitivity	92.10	75
Specificity	66.66	88
Positive predictive value	89.70	54
Negative predictive value	72.70	94

5. Discussion

Ovarian cancer is one of the leading causes of death in female patients. Presentation varies from asymptomatic to distant metastasis. Ultrasound, being widely used and easily available, can be used as the first modality in evaluating ovarian masses. There are specific imaging features (3, 21) of some ovarian pathologies that are characteristic of that particular lesion, which makes the diagnosis easy, like in the case of Hemorrhagic cysts, Endometriotic cysts, and dermis. The present study aims to distinguish benign and malignant ovarian masses in early management, decrease ambiguity, and avoid unnecessary surgery in benign lesions. HPE is used as a gold standard tool to compare the results. In the present study, ovarian lesions were found to be most common between the age group of 26 - 40 of life (n = 22, 44%).

In the present study, the most common age group with ovarian masses was between the age group of 26-40 (n = 22, 44%), which is comparable to the study by Garg et al. (n = 24, 48%). The next most common age group with ovarian masses was between the age group of 41-55 (n = 12, 24%), whereas Garg et al. found the next most common group between the age group of 56 - 70 (n = 13, 26%) (22).

In the present study, the most common lesions were benign, accounting for 76% (n = 38), concordant with the study by Garg et al. (22) In the present study, serous cystadenomas are the most common benign lesions (n = 16, 32%). Serous Cystadenocarcinoma is the most common malignant ovarian pathology (n = 4, 8%).

4.1. USG Characteristics

Unilocular ovarian masses are the most common ovarian pathology (n = 33, 66%). Well-defined lesions are the most common (n = 42, 84%). Septations were seen in 11 cases, 22%. Solid components were seen in 5 cases, 10%. Among the B features, the B5 feature is the most common (n = 32, 64%), i.e., color score 0 (no blood flow), followed by the B1 feature (n = 30, 60%), i.e., Unilocular cyst < 10cm, which is concordant with the study done by Garg et al. (22) Among the M features, the M4 feature is the most common (n = 5, 10%), i.e., irregular multilocular solid ovarian lesions, followed by the M1 feature (n = 4, 8%), i.e., the irregular solid tumor, which is discordant with the study done by Garg et al. (22) which showed M1, M2, M3 Showing equal prevalence followed by M5. The discordance is due to the inclusion of infective and adnexal pathologies. In the present study, color score 1 is the most common (n = 38, 76%), i.e., no blood flow. Overall, most of the pathologies were benign (76%), well-defined (84%), unilateral (86%), and unilocular (66%).

4.2. USG and HPE Diagnosis

A total of 36 cases were verified histologically. Twenty-six cases were considered benign based on IOTA USG rules, of which 23 turned out benign, and 3 became malignant his-

tologically. Eight cases were considered malignant based on IOTA USG rules, out of which 6 turned out to be malignant, and 2 turned out to be benign. Four cases were considered indeterminate, out of which 2 cases were benign and 2 were malignant histologically.

A total of 8 cases were simple ovarian cysts, and 6 cases were hemorrhagic cysts for which histopathological examination was not done. Based on specific features (3, 21), IOTA USG RULES and follow-up were confirmed benign.

5.1. Limitation

The present study has a small sample size.

5.2. Conclusions

USG is an easily available imaging tool that can be used as an initial modality in evaluating ovarian masses. IOTA simple ultrasound rules have diagnostic accuracy in distinguishing benign and malignant ovarian masses and help in management.

Authors' contributions

Dr. Amatul Kareem Sumaya: Conceptualization, formal analysis, resources; Dr. Banavath Swetha: Validation, Formal analysis; Dr. Aithagani Ramachandraiah: Writing original Draft, Data curation, Methodology, resources; Dr. Nadeem Ahmed: Formal analysis, Writing - Review; Dr. Sunitha Bajaj: Methodology, Formal analysis.

Conflict of interests

No competing interest was recorded.

Data reproducibility

Data was made available by the corresponding author.

Ethics approval and consent to participate

Patient consent was taken.

Funding

There was no funding for the research.

References

1. Tewari KS, Monk BJ. *The 21st Century Handbook of Clinical Ovarian Cancer*. ADIS; 2015.
2. Verkauf BS, Bernhisel MA. Ovarian maldescent. *Fertil Steril*. 1996;**65**(1):189-92. [PubMed ID:8557139]. [https://doi.org/10.1016/S0015-0282\(16\)58050-9](https://doi.org/10.1016/S0015-0282(16)58050-9).
3. Timmerman D, Testa AC, Bourne T, Ferrazzi E, Ameye L, Konstantinovic ML, et al. Logistic regression model to distinguish between the benign and malignant adnexal mass before surgery: a multicenter study by the International Ovarian Tumor Analysis Group. *J Clin Oncol*. 2005;**23**(34):8794-801. [PubMed ID:16314639]. <https://doi.org/10.1200/JCO.2005.01.7632>.
4. Timmerman D, Testa AC, Bourne T, Ameye L, Jurkovic D, Van Holsbeke C, et al. Simple ultrasound-based rules for the diagnosis of ovarian cancer. *Ultrasound Obstet Gynecol*. 2008;**31**(6):681-90. [PubMed ID:18504770]. <https://doi.org/10.1002/uog.5365>.
5. Kaijser J, Bourne T, Valentin L, Sayasneh A, Van Holsbeke C, Vergote I, et al. Improving strategies for diagnosing ovarian cancer: a summary of the International Ovarian Tumor Analysis (IOTA) studies. *Ultrasound Obstet Gynecol*. 2013;**41**(1):9-20. [PubMed ID:23065859]. <https://doi.org/10.1002/uog.12323>.
6. Fathallah K, Huchon C, Bats AS, Metzger U, Lefrere-Belda MA, Bensaid C, et al. [External validation of simple ultrasound rules of Timmerman on 122 ovarian tumors]. *Gynecol Obstet Fertil*. 2011;**39**(9):477-81. French. [PubMed ID:21820936]. <https://doi.org/10.1016/j.gyobfe.2011.05.007>.

7. Hartman CA, Juliato CR, Sarian LO, Toledo MC, Jales RM, Morais SS, et al. Ultrasound criteria and CA 125 as predictive variables of ovarian cancer in women with adnexal tumors. *Ultrasound Obstet Gynecol.* 2012;**40**(3):360-6. [PubMed ID:22648861]. <https://doi.org/10.1002/uog.11201>.
8. Alcazar JL, Pascual MA, Olartecoechea B, Graupera B, Auba M, Ajossa S, et al. IOTA simple rules for discriminating between benign and malignant adnexal masses: prospective external validation. *Ultrasound Obstet Gynecol.* 2013;**42**(4):467-71. [PubMed ID:23576304]. <https://doi.org/10.1002/uog.12485>.
9. Sayasneh A, Wynants L, Preisler J, Kaijser J, Johnson S, Stalder C, et al. Multicentre external validation of IOTA prediction models and RMI by operators with varied training. *Br J Cancer.* 2013;**108**(12):2448-54. [PubMed ID:23674083]. [PubMed Central ID:3694231]. <https://doi.org/10.1038/bjc.2013.224>.
10. Tantipalakov C, Wanapirak C, Khunamornpong S, Sukpan K, Tongsong T. IOTA simple rules in differentiating between benign and malignant ovarian tumors. *Asian Pac J Cancer Prev.* 2014;**15**(13):5123-6. [PubMed ID:25040961]. <https://doi.org/10.7314/apjcp.2014.15.13.5123>.
11. Nunes N, Ambler G, Foo X, Naftalin J, Widschwendter M, Jurkovic D. Use of IOTA simple rules for diagnosis of ovarian cancer: meta-analysis. *Ultrasound Obstet Gynecol.* 2014;**44**(5):503-14. [PubMed ID:24920435]. <https://doi.org/10.1002/uog.13437>.
12. Tinnangwattana D, Vichak-Ururrote L, Tontivuthikul P, Charoenratana C, Lerthiranwong T, Tongsong T. IOTA Simple Rules in Differentiating between Benign and Malignant Adnexal Masses by Non-expert Examiners. *Asian Pac J Cancer Prev.* 2015;**16**(9):3835-8. [PubMed ID:25987045]. <https://doi.org/10.7314/apjcp.2015.16.9.3835>.
13. Ruiz de Gauna B, Rodriguez D, Olartecoechea B, Auba M, Jurado M, Gomez Roig MD, et al. Diagnostic performance of IOTA simple rules for adnexal masses classification: a comparison between two centers with different ovarian cancer prevalence. *Eur J Obstet Gynecol Reprod Biol.* 2015;**191**:10-4. [PubMed ID:26066289]. <https://doi.org/10.1016/j.ejogrb.2015.05.024>.
14. Knafel A, Banas T, Nocun A, Wiechec M, Jach R, Ludwin A, et al. The Prospective External Validation of International Ovarian Tumor Analysis (IOTA) Simple Rules in the Hands of Level I and II Examiners. *Ultraschall Med.* 2016;**37**(5):516-23. [PubMed ID:26126150]. <https://doi.org/10.1055/s-0034-1398773>.
15. Meinhold-Heerlein I, Fotopoulou C, Harter P, Kurzeder C, Mustea A, Wimberger P, et al. The new WHO classification of ovarian, fallopian tube, and primary peritoneal cancer and its clinical implications. *Arch Gynecol Obstet.* 2016;**293**(4):695-700. [PubMed ID:26894303]. <https://doi.org/10.1007/s00404-016-4035-8>.
16. Royal College of Obstetricians and Gynecologists. *Management of Suspected Ovarian Masses in Premenopausal Women (Green-top Guideline No. 62)*. Royal College of Obstetricians and Gynecologists; 2015.
17. Woo YL, Kyrgiou M, Bryant A, Everett T, Dickinson HO. Centralisation of services for gynaecological cancers - a Cochrane systematic review. *Gynecol Oncol.* 2012;**126**(2):286-90. [PubMed ID:22507534]. <https://doi.org/10.1016/j.ygyno.2012.04.012>.
18. Engelen MJ, Kos HE, Willemsse PH, Aalders JG, de Vries EG, Schaapveld M, et al. Surgery by consultant gynecologic oncologists improves survival in patients with ovarian carcinoma. *Cancer.* 2006;**106**(3):589-98. [PubMed ID:16369985]. <https://doi.org/10.1002/cncr.21616>.
19. Vernooij F, Heintz AP, Witteveen PO, van der Heiden-van der Loo M, Coebergh JW, van der Graaf Y. Specialized care and survival of ovarian cancer patients in The Netherlands: nationwide cohort study. *J Natl Cancer Inst.* 2008;**100**(6):399-406. [PubMed ID:18334710]. <https://doi.org/10.1093/jnci/djn033>.
20. Earle CC, Schrag D, Neville BA, Yabroff KR, Topor M, Fahey A, et al. Effect of surgeon specialty on processes of care and outcomes for ovarian cancer patients. *J Natl Cancer Inst.* 2006;**98**(3):172-80. [PubMed ID:16449677]. <https://doi.org/10.1093/jnci/djj019>.
21. Sayasneh A, Kaijser J, Preisler J, Johnson S, Stalder C, Husicka R, et al. A multicenter prospective external validation of the diagnostic performance of IOTA simple descriptors and rules to characterize ovarian masses. *Gynecol Oncol.* 2013;**130**(1):140-6. [PubMed ID:23578539]. <https://doi.org/10.1016/j.ygyno.2013.04.003>.
22. Garg S, Kaur A, Mohi JK, Sibia PK, Kaur N. Evaluation of IOTA Simple Ultrasound Rules to Distinguish Benign and Malignant Ovarian Tumours. *J Clin Diagn Res.* 2017;**11**(8):TC06-TC9. [PubMed ID:28969237]. [PubMed Central ID:5620878]. <https://doi.org/10.7860/JCDR/2017/26790.10353>.